

Author Affiliation:

*Department of Urology,
Department of Obstetrics & Gynaecology, * Department of Surgery, Bharti Hospital and Research Center, Pune-Satara Road, Dhankawadi, Pune-411043, Maharashtra, India.

Reprint Request:

Sanjay Prakash Dhangar, B-704, Aster Trinity, Sai baba nagar, Survey no 62, KondhwaKhurd, Pune - 411048, Maharashtra, India.
E-mail: sanjayamrapali18@gmail.com

Surgical Therapy in Infertile Men with Obstructive Azoospermia Due to Ejaculatory Duct Obstruction–Outcome after Transurethral Resection of Ejaculatory Duct

Sanjay Prakash Dhangar*, **Ibrahim H. Kothawala***, **A.D. Gosavi****, **Arefakothawala****, **Abhay Kumar*****, **Sachin Patil***

Abstract

Objectives: To report our experience with transurethral resection of ejaculatory ducts (TURED) in infertile men with symptomatic ejaculatory duct obstruction. **Material and Method:** We studied 4 cases of ejaculatory duct obstruction from January 2014 to January 2015. Investigations included a history, physical examination, semen analysis, semen culture, hormone levels and trans-rectal ultrasonography. Results were evaluated after TURED, especially the semen parameters, the patency and the pregnancy rate. **Results:** Causes of obstruction were previous infection with inflammation, calculus and prostatic cyst. Mean age was 34 years. Mean Duration of infertility was 3.5 years. Mean FSH value was 1.5. Mean Semen volume was 0.5 ml with SD of ± 0.10 m. In all patients fructose was absent on semen analysis. On TRUS mean seminal vesicle diameter was 16.00 mm Seminal vesicle was dilated in all cases. In 3/4 patients who had patency in follow up had a mean sperm count of 14.33 million/ml. Mean time to patency was 3 months. Post TURED ejaculate volume improved in all patients with mean of 1.75ml and SD of 0.50 ml. Patients who had undergone TURED reported a patency rate of 75 %, with one patient showing absence of sperms in follow up. After TURED on follow up pregnancy was reported in one case i.e. 25 %. In our study mean follow up was 10 months. **Conclusions:** Men with symptomatic EDO who underwent TURED showed improvements in their ejaculation, sensation of orgasm, semen analysis values and fertility.

Keywords: Ejaculatory Duct Obstruction; Infertility; Ejaculatory Duct/Prostatic Cyst; Transurethral resection of Ejaculatory Duct; Tured.

Introduction: Infertility by itself does not threaten the life, but it has devastating psycho-social consequences on infertile couples. It remains a worldwide problem and challenge. Management of infertility has been and still a difficult medical task not only because of the difficulty in the diagnosis and treatment of the reproductive disorders in each partner, or the poorly unstated interaction between the partners' fertility potentials, but also because of the fact that success of treatment is clearly identifiable entity - the achievement of pregnancy. By following the *evidence-based* management protocol infertile couples will have a good chance to start up their treatment in the proper way at early time [1].

Azoospermia, defined as complete absence of sperm from the ejaculate, is present in less than 2% of all men and in 15% of infertile men [2].

Among infertile men, the incidence of azoospermia is about 10 to 15%, of which 40% is due to obstructive azoospermia [3].

Causes of obstructive azoospermia are vasectomy, congenital absence of vas deferens and ejaculatory duct obstruction, and acquired diseases (eg. epididymal obstruction secondary to infection, vasal injury due to previous inguino-scrotal surgery) [4].

There are few diagnoses in azoospermic men that

are amenable to surgical correction. The most common among these are epididymal obstruction, vasectomy and obstruction of the ejaculatory ducts. The importance of diagnosing these conditions and treating them appropriately lies in the fact that they can be cured [4].

Ejaculatory duct obstruction (EDO) is reported to be the cause of azoospermia in up to 5% of patients [5].

In the present study we assessed and provided the evidence for the effectiveness of surgical treatment of ejaculatory duct obstruction.

Objectives

To report our experience with transurethral resection of ejaculatory ducts (TURED) in infertile men with symptomatic ejaculatory duct obstruction and to assess the patency rate after trans-urethral resection of ejaculatory ducts.

Material and Methods

This study was carried out in Bharti Hospital and Research Center, Pune during the period January 2014 to January 2015. This study was done on 4 patients of Obstructive Azoospermia who were subjected to Transurethral resection of Ejaculatory ducts (TURED).

Ethics

The study protocol was reviewed and approved by institutional ethical and scientific committee and informed consent was obtained.

Statistics

Data analysis was carried out under the guidance of our statistics expert, using Statistical Package for Social Sciences version 17.

The Inclusion Criteria for TURED

1. The preoperative symptoms like infertility, non-projectile ejaculation, a decrease in sensation of orgasm, and/or pain with ejaculation, history of prostatitis or epididymitis, perineal or testicular pain.
2. Low volume ejaculate
3. Bilateral palpable vas deferens
4. Normal hormonal profile

5. Dilated seminal vesicles on trans-rectal ultrasonography (TRUS)

The preoperative symptoms included infertility, non-projectile ejaculation, a decrease in sensation of orgasm, and/or pain with ejaculation etc. Investigations included a focused history and physical examination, two semen analyses, a semen culture (with PCR analysis), and TRUS. On TRUS, each man was evaluated for prostatic calcifications, ejaculatory duct cysts and the diameter of the seminal vesicles. Seminal vesicles were considered dilated when they were more than 15mm in diameter.

Surgical Technique

All operations were done under regional anaesthesia. Cystoscopy was performed and the bladder was inspected. Cysto-urethroscopy findings such as midline cysts and altered verumontanum anatomy etc. were recorded. A drape is used with a finger in the rectum to allow better depth perception and visualization of the posterior prostate. Using a transurethral resection set, cystic lesions were opened. If an ejaculatory duct cyst is present, it is usually deep and just posterior to the verumontanum. Therefore, the verumontanum is deeply resected with care not to injure the rectum. Once efflux from the ejaculatory ducts of copious cloudy material is present, the resection was considered adequate. Electrocautery is used judiciously to avoid occlusion of the newly opened ejaculatory ducts. Care is taken at all times to protect the bladder neck and external sphincter from injury that might result in retrograde ejaculation and urinary incontinence. A Foley catheter is left overnight and the patient was discharged next day. All the patients received a 5- to 7-day course of antibiotics. Vasogram or seminal vesiculogram were not done.

Postoperative Evaluation

All patients were assessed at 6 weeks and 3 months and included focused history about improvements in symptoms of EDO and semen analyses and continued until pregnancy was achieved. Patency was defined as the presence of motile sperm in the ejaculate of at least one postoperative semen sample. Pregnancy was defined as unassisted establishment (no assisted reproduction) of a viable pregnancy leading to a live birth. Follow-up information was obtained from clinic visits and telephone contact.

Results

Etiology

In 50 % of patients with ejaculatory duct obstruction had history of previous infection with inflammation as a cause of obstruction. Other 25% had calculus and prostatic cyst as obstructive etiology [Figure 1].

Descriptive Statistics (Pre-operative parameters) [Table 1]

In 4 Patients who has Undergone TURED

- i. Mean age was 34 with standard deviation of ± 2.65 with minimum age of patient seen was 32 and maximum age was 38 years.
- ii. Mean Duration of infertility was 3.5 years with standard deviation of ± 2.38 . Minimum duration of infertility was 1 year and maximum was 6 years.
- iii. Mean FSH value was 1.5 with SD of ± 0.58
- iv. Mean Semen volume was 0.5 ml with SD of ± 0.10 ml. Minimum semen volume was 0.4 ml and maximum was 0.6 ml.

Fructose in Semen Analysis

In all patients who underwent TURED due to ejaculatory duct obstruction fructose was absent on semen analysis.

Patency in TURED Patients

Patients who had undergone TURED reported a patency rate of 75 %, with one patient showing absence of sperms in follow up.

Table 1: Descriptive Statistics (Pre-operative parameters)

	N	Minimum	Maximum	Mean	Std. Deviation
Age	4	32	38	34.50	2.65
Duration of Primary infertility(years)	4	1yr	6 yrs	3.50	2.38
FSH	4	1.0	2.0	1.50	0.58
Semen volume	4	0.4ml	0.6ml	0.53	0.10

Table 2: Descriptive Statistics (post-operative parameters)

	N	Minimum	Maximum	Mean	Std. Deviation
Operative time	4	70	90	77.50	9.57
Sperm density (million/ml)	3	9	22	14.33	6.81
Time to patency (month)	3	2	4	3	1
Follow up(month)	4	8	12	10.00	1.63
On TRUS Seminal Vesicle in Millimeters (mm)	4	15	17	16.00	0.82
Post TURED ejaculate vol.	4	1	2	1.75	0.50

Pregnancy Rate Post TURED

After TURED on follow up pregnancy was reported in one case i.e. 25 %.

Descriptive Statistics (Post-Operative Parameters) [Table 2]

In 4 Patients who has Undergone TURED

- i. Mean operative time was 77 minutes with SD of ± 9.57 . Minimum operative time required was 70 minutes and maximum operative time was 90 minutes.
- ii. In 3/4 patients who had patency in follow up had a mean sperm count of 14.33 million/ml with SD of ± 6.81 . Minimum sperm density seen was 9 million/ml and maximum was 22 million /ml.
- iii. Mean time to patency was 3 months with SD of ± 1.0 . Minimum time required for patency was 2 months and maximum time was 4 months.
- iv. In our study mean follow up was 10 months with SD of ± 1.63 . Minimum follow up was 8 months and maximum was 12 months.
- v. On TRUS mean seminal vesicle diameter was 16.00 mm with SD of 0.82 mm. One patient had diameter of 17 mm while others have diameter more than 15 mm. Seminal vesicle was dilated in all cases.
- vi. Post TURED ejaculate volume improved in all patients with mean of 1.75ml and SD of 0.50 ml.

Complications with TURED are rare if the procedure is done carefully and with expertise. In our study, overall there were no complications associated with the procedure.

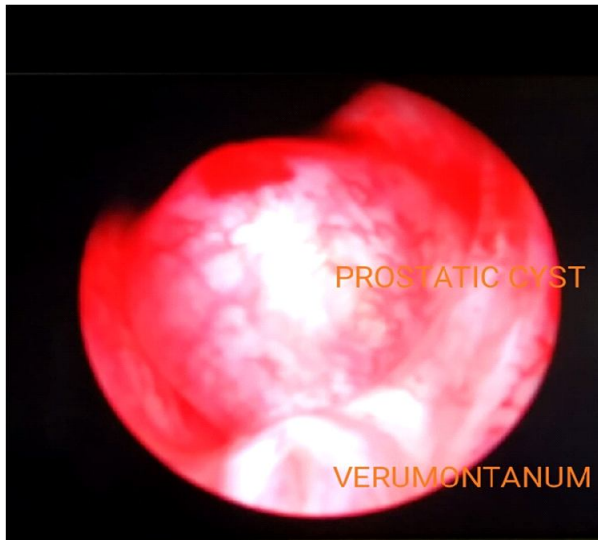


Fig. 1:

Discussion

For patients with obstructive azoospermia, surgical therapy is an acceptable management option in comparison with assisted reproduction techniques (ART) such as ICSI, which tend to bypass the male factor etiology. Surgical correction offers a long-term solution and aims at correcting the underlying pathology. It also obviates the need for repeated ART each time the individual wishes to contribute to a pregnancy.

Ejaculatory duct obstruction is a rare cause of infertility, but it is essential to diagnose it, as it can be easily corrected with a minor cystoscopic procedure. Detecting Ejaculatory duct obstruction has become easier and less invasive with the development of high resolution TRUS, which by itself has been shown to be very effective for identifying possible EDO. It can show cysts or calcifications that might cause blockage, and identifies dilated seminal vesicles.

In patients with suspected EDO, TURED has become the standard procedure. It was described by Farley and Barnes in 1973 [6].

Etiology

Etiology of EDO is varied. Ejaculatory duct obstruction can be either congenital or acquired. Congenital causes include congenital atresia or stenosis of the ejaculatory ducts and utricular, mullerian, and wolffian duct cysts. Acquired causes may be secondary to trauma, either iatrogenic or otherwise, or infectious or inflammatory aetiologies.

Calculus formation secondary to infection may also cause obstruction [7]. In our study 50 % of patients with ejaculatory duct obstruction had history of previous infection with inflammation as a cause of obstruction. Other 25% had calculus and prostatic cyst each as obstructive etiology. Paick J et al [8] in his study of 50 men the main cause of EDO was a midline cyst in 16, Wolffian malformation in four, tuberculosis in 17, previous genitourinary infection in five and idiopathic in eight men. In 17 patients the seminal vesicles appeared to be atrophied on TRUS; 15 of these patients had a history of pulmonary tuberculosis and subsequent vasography in five showed multiple bilateral vasal obstruction. Tu XA et al [9] in their study had 6 prostatic cyst and 3 cases of calcification out of total 60 cases.

Age

Patients of EDO are usually young individuals. In our study mean age was 34 with standard deviation of ± 2.65 with minimum age of patient seen was 32 and maximum age was 38 years. Ozgok Y et al [10] in his study of 24 patients had mean age of 29 years with variation between 20 and 40 years (mean=29). Kochakarn W et al [11] in his study of 7 patients has age range from 32-45 years old (mean 34.5).

Duration of Infertility

In our study duration of infertility was 3.5 years with standard deviation of ± 2.38 . Minimum duration of infertility was 1 year and maximum was 6 years.

Serum FSH Levels

Mean FSH value was 1.5 with SD of ± 0.58 in our study. Kochakarn W et al [11] in his study of 7 patients had seventy-one per cent patients with normal hormonal profiles and twenty-nine per cent had a slight increase of FSH, LH but not more than one fold of normal range.

Semen Values

Mean Semen volume was 0.5 ml with SD of ± 0.10 ml in our study. Minimum semen volume was 0.4 ml and maximum was 0.6 ml. In the study by Christopher W et al R [12], the mean ejaculate volume before TURED was 1.1 mL. In study by Immo-Schroeder-Printzen et al [13], sperm analysis pre-operatively demonstrated typical low-volume ejaculates with azoospermia, ejaculate volume was between 0.5 and 1.6 ml (mean 0.95 ml) and seminal

pH was acidic in every case.

Fructose in Semen Analysis

In all patients who had undergone TURED due to ejaculatory duct obstruction fructose was absent on semen analysis. Immo-Schroeder-Printzen et al [13] in their of 16 patients with EDO, fructose was absent or below 13 $\mu\text{mol}/\text{ejaculate}$. Testicular volumes, serum FSH and spermatogenesis (Johnson score >8) were normal in all cases.

TRUS Findings

TRUS is certainly the easiest way to detect cystic lesions at the verumontanum level as well as dilatations of the internal ductal diameter and of the seminal vesicles. On TRUS mean seminal vesicle diameter was 16.00 mm with SD of ± 0.82 mm in our study. Christopher W et al [12] On TRUS, each man was evaluated for prostatic calcifications, ejaculatory duct cysts and the diameter of the seminal vesicles. Seminal vesicles were considered dilated when they were = 12 mm in diameter. In study by Immo-Schroeder-Printzen et al [13] TRUS findings cover midline utricular and Müllerian cysts, as well as dilated ejaculatory ducts, defined with an internal ductal diameter >2.3 mm and/or dilated seminal vesicles with a cross-sectional diameter >15 mm.

Operative Time

Mean operative time was 77 minutes with SD of ± 9.57 . Minimum operative time required was 70 minutes and maximum operative time was 90 minutes.

Post Tured ejaculate Volume

Post TURED ejaculate volume improved in all patients with mean of 1.75ml and SD of ± 0.50 ml. Christopher W et al [12] The mean ejaculate volume after TURED increased to 2.3 mL.

Sperm Count

In 3/4 patients who had patency in follow up had a mean sperm count of 14.33 million / ml with SD of ± 6.81 . Minimum sperm density seen was 9 million/ml and maximum was 22 million /ml. In study by Christopher W et al [12], the total motile sperm count increased 38.1 million per ejaculate. Ozgok Y et al [10] in his study of 24 patients before transurethral resection mean sperm count was $1.66 \times 10^6/\text{ml}$ compared to $25.4 \times 10^6/\text{ml}$ postoperatively.

Kochakarn W et al [11] in his study of 7 patients 6 of 7 (86%) showed improvement of semen analysis. Up to one year, 6 of 7 (86%) have normal semen analysis and another one still had azoospermia.

Time to Patency

Mean time to patency was 3 months with SD of ± 1.0 . Minimum time required for patency was 2 months and maximum time was 4 months.

Patency in Tured Patients

Patients who had undergone TURED reported a patency rate of 75%, with one patient showing absence of sperms. Yurdakul t et al [14] in his study before TURED, all patients were azoospermic, following the operation, sperms were seen in the ejaculates of 11/12 patients. Immo-Schroeder-Printzen et al in their of 16 patients with EDO had post-operative ejaculates showing patency in all patients with Mullerian cysts. There was an improvement in sperm counts in all Mullerian cyst patients with successful opening but only an improvement in two patients without cystic lesions. The worst results were obtained in all patients with lateral cystic lesions of the ductus ejaculatorius.

Pregnancy Rate Post Tured

After TURED on follow up pregnancy rate was reported to be 25% with follow up period of 8 – 12 months. In study by Christopher W et al [12] four of the six men available for long-term follow-up reported successful paternity without assisted reproduction techniques. In study by Yurdakul t et al [14] after a mean follow-up period of 12 (range 4-36) months, five (41.6%) pregnancies were noted. Ozgok Y et al [10] in his study of 24 patients had a mean follow-up period of 9 (6-18) months, 6 (25%) pregnancies were noted. Kochakarn W et al [11] in his study of 7 patients had a long-term follow-up, 4 of 7 (57%) were able to impregnate their wives. TuXa et al [15] in his evaluation of 43 men with EDO treated by TURED, 36 (83.7%) showed improved semen parameters and 11 (25.6%) achieved pregnancies. Weintraub et al [16] reported 25% pregnancy rate in their study of eight patients with ejaculatory duct obstruction.

Follow up

In our study mean follow up was 10 months with SD of ± 1.63 . Minimum follow up was 8 months and maximum was 12 months.

Conclusion

Abnormalities of the distal ejaculatory ducts especially related to infertility have been well documented with the advent and increased use of high-resolution TRUS. In an infertile male with oligospermia or azoospermia with low ejaculate volume, normal secondary sex characteristics, testes, and hormonal profile, and dilated seminal vesicles, midline cyst, or calcification on TRUS, ejaculatory duct obstruction is suggested. EDO is a very treatable disease that can be cured with a simple cystoscopic procedure. This treatment has a positive impact not only on fertility, but also on sexual satisfaction. Men with symptomatic EDO who underwent TURED showed improvements in their ejaculation, sensation of orgasm, semen analysis values and fertility.

Genetic testing and counseling should be considered in appropriate cases, because genetic factors may impact both the patient and his potential offspring, also not all patients post successful TURED are able to impregnate their spouse.

Current technology often allows for paternity for men previously labeled sterile. In general, if possible, it is preferable to improve the male's fertility potential and allow the couple to conceive by intercourse. This is not only economic but also provides the males great mental satisfaction.

Limitations

This is a non-randomised clinical study to evaluate TURED results. The availability of necessary instruments and expertise made the study feasible. However, long term prospective trials are necessary to validate the durability of this therapy and its effect on the symptoms of EDO.

Acknowledgements

Mr Shrivallabh Sane (Statistician) for contribution in statistical analysis.

Financial Support and Sponsorship: Nil

Conflicts of Interest: None

References

1. Remah M Kame *Reprod Biol Endocrinol.* Management of the infertile couple: an evidence-

based protocol. 2010; 8: 21.

2. Jonathan Jarow, Peter N. Kolettis, The Management of Obstructive Azoospermia: AUA Best Practice Statement, American Urological Association 2010; 1-23.
3. KL HO, MH Wong, PC Tam, Microsurgical vasoepididymostomy for obstructive azoospermia, *Hong Kong Med J.* 2009; 15: 452-7.
4. Kumar R. Surgery for azoospermia in the Indian patient: Why is it different? *Indian J Urol.* 2011; 27: 98-101.
5. Purohit R, Wu R, Shinohara K, Turek PJ. Ejaculatory Duct Obstruction and Resection. *J Urol.* 2004; 171: 232-236.
6. Joo Yong Lee, Richilda Red Diaz, Young Deuk Choi, and Kang Su Cho. Hybrid Method of Transurethral Resection of Ejaculatory Ducts Using Holmium:Yttriumaluminium Garnet Laser on Complete Ejaculatory Duct Obstruction: *Yonsei Med J.* 2013 Jul 1; 54(4): 1062-1065.
7. Harry Fisch, Young M. Kang, Christopher W. Johnson and Erik T. Goluboff. Ejaculatory duct obstruction: *Curr Opin Urol.* 2002; 12: 509-515.
8. J Paick, S H Kim, Ejaculatory duct obstruction in infertile men., *BJU International.* 2000; 85: 720- 724.
9. Tu XA, Zhao LY, Zhao L, Wang WW, Deng LW, Chen Y, Deng CH. Efficacy of transurethral resection of ejaculatory duct for treatment of ejaculatory duct obstruction: report of 60 cases. *Beijing Da XueXueBao.* 2011 Aug 18; 43(4): 559-61.
10. Ozgok Y Tan Mo Diagnosis and treatment of ejaculatory duct obstruction in male infertility. *Eur Urol.* 2001 Jan; 39(1): 24-9.
11. Kochkaraw ,Muangman V Ejaculatory duct obstruction in the infertile male: experience of 7 cases at RamathibodiJ *Med Assoc Thai.* 2001 Aug; 84(8): 1148-52.
12. Christopher W. Johnson, Jonathan B, Transurethral resection of the ejaculatory ducts fortreating ejaculatory symptom, *BJU international.* 2005; 95: 117-119 .
13. Immo Schroeder-Printzen et al Surgical therapy in infertile men with ejaculatory duct obstruction: technique and outcome of a standardized surgical approach Department of Urology University, Klinikstr. 29, D-35392 Giessen, Germany.
14. Yurdakul T, Gokce G, Kilic O, Piskin MM Transurethral resection of ejaculatory ducts in the treatment of complete ejaculatory duct obstruction. *IntUrolNephrol.* 2008; 40(2): 369-72.
15. Tu XA, Zhao LY, Deng LW, Wang WW, Zhao L, Liang H, Zeng LY, Deng CH. [Surgical treatment of obstructive azoospermia: a report of 56 cases] *Zhonghua Nan KeXue.* 2010 Jan; 16(1): 48-51.
16. Weintraub MP, De Mouy E, Hellstrom WJ. Newer modalities in the diagnosis and treatment of ejaculatory duct obstruction. *J Urol.* 1993; 150: 1150-1154.